



Online article and related content
current as of June 3, 2009.

Surveillance of BRCA1 and BRCA2 Mutation Carriers With Magnetic Resonance Imaging, Ultrasound, Mammography, and Clinical Breast Examination

Ellen Warner; Donald B. Plewes; Kimberley A. Hill; et al.

JAMA. 2004;292(11):1317-1325 (doi:10.1001/jama.292.11.1317)

<http://jama.ama-assn.org/cgi/content/full/292/11/1317>

Correction	Contact me if this article is corrected.
Citations	This article has been cited 208 times. Contact me when this article is cited.
Topic collections	Oncology; Breast Cancer; Radiologic Imaging; Magnetic Resonance Imaging; Mammography; Ultrasonography Contact me when new articles are published in these topic areas.
Related Articles published in the same issue	Breast MRI for Women With Hereditary Cancer Risk Mark E. Robson et al. <i>JAMA</i>. 2004;292(11):1368.
Related Letters	Surveillance of BRCA1 and BRCA2 Carriers Mark Helvie. <i>JAMA</i>. 2005;293(8):931.
	In Reply: Ellen Warner et al. <i>JAMA</i>. 2005;293(8):931.

Subscribe
<http://jama.com/subscribe>

Permissions
permissions@ama-assn.org
<http://pubs.ama-assn.org/misc/permissions.dtl>

Email Alerts
<http://jamaarchives.com/alerts>

Reprints/E-prints
reprints@ama-assn.org

Surveillance of *BRCA1* and *BRCA2* Mutation Carriers With Magnetic Resonance Imaging, Ultrasound, Mammography, and Clinical Breast Examination

Ellen Warner, MD

Donald B. Plewes, PhD

Kimberley A. Hill, BA

Petrina A. Causer, MD

Judit T. Zubovits, MD

Roberta A. Jong, MD

Margaret R. Cutrara, RN

Gerrit DeBoer, PhD

Martin J. Yaffe, PhD

Sandra J. Messner, MD

Wendy S. Meschino, MD

Cameron A. Piron, MSc

Steven A. Narod, MD

WOMEN WITH *BRCA1* AND *BRCA2* mutations who do not undergo prophylactic surgery have a lifetime risk of breast cancer of up to 85%, with a significantly higher risk of breast cancer than the general population from age 25 years onward.¹ It has been recommended that breast cancer surveillance for these women include monthly breast self-examination beginning at 18 to 20 years, semiannual clinical breast examination (CBE) by a health care professional beginning between 20 and 35 years, and annual mammography beginning from 25 to 35 years.^{2,3} These recommendations are based on expert opinion; there has been no prospective study demonstrating a benefit of

For editorial comment see p 1368.

Context Current recommendations for women who have a *BRCA1* or *BRCA2* mutation are to undergo breast surveillance from age 25 years onward with mammography annually and clinical breast examination (CBE) every 6 months; however, many tumors are detected at a relatively advanced stage. Magnetic resonance imaging (MRI) and ultrasound may improve the ability to detect breast cancer at an early stage.

Objective To compare the sensitivity and specificity of 4 methods of breast cancer surveillance (mammography, ultrasound, MRI, and CBE) in women with hereditary susceptibility to breast cancer due to a *BRCA1* or *BRCA2* mutation.

Design, Setting, and Participants A surveillance study of 236 Canadian women aged 25 to 65 years with *BRCA1* or *BRCA2* mutations who underwent 1 to 3 annual screening examinations, consisting of MRI, mammography, and ultrasound at a single tertiary care teaching hospital between November 3, 1997, and March 31, 2003. On the day of imaging and at 6-month intervals, CBE was performed.

Main Outcome Measures Sensitivity and specificity of each of the 4 surveillance modalities, and sensitivity of all 4 screening modalities vs mammography and CBE.

Results Each imaging modality was read independently by a radiologist and scored on a 5-point Breast Imaging Reporting and Data System scale. All lesions with a score of 4 or 5 (suspicious or highly suspicious for malignancy) were biopsied. There were 22 cancers detected (16 invasive and 6 ductal carcinoma in situ). Of these, 17 (77%) were detected by MRI vs 8 (36%) by mammography, 7 (33%) by ultrasound, and 2 (9.1%) by CBE. The sensitivity and specificity (based on biopsy rates) were 77% and 95.4% for MRI, 36% and 99.8% for mammography, 33% and 96% for ultrasound, and 9.1% and 99.3% for CBE, respectively. There was 1 interval cancer. All 4 screening modalities combined had a sensitivity of 95% vs 45% for mammography and CBE combined.

Conclusions In *BRCA1* and *BRCA2* mutation carriers, MRI is more sensitive for detecting breast cancers than mammography, ultrasound, or CBE alone. Whether surveillance regimens that include MRI will reduce mortality from breast cancer in high-risk women requires further investigation.

JAMA. 2004;292:1317-1325

www.jama.com

surveillance on cancer-specific mortality in this population. Eight randomized clinical trials of mammography

have been conducted in the general population⁴ but it is expected that fewer than 1% of the study participants in

Author Affiliations: Division of Medical Oncology, Department of Medicine (Dr Warner and Mss Hill and Cutrara), Imaging Research and Department of Medical Biophysics (Drs Plewes, DeBoer, and Yaffe, and Mr Piron), Department of Medical Imaging (Drs Causer and Jong), Department of Pathology (Dr Zubovits), Division of Clinical Trials and Epidemiology (Dr DeBoer), Departments of Preventive Oncology and Family and Community Medicine (Dr Messner), and Center for

Research in Women's Health (Dr Narod), Sunnybrook and Women's College Health Sciences Centre and University of Toronto; and Department of Genetics, North York General Hospital (Dr Meschino), Toronto, Ontario.

Corresponding Author: Ellen Warner, MD, Division of Medical Oncology, Toronto-Sunnybrook Regional Cancer Centre, 2075 Bayview Ave, Toronto, Ontario, Canada M4N 3M5 (ellen.warner@sw.ca).

these trials would have a *BRCA* mutation. Nonrandomized observational studies of cohorts of *BRCA* mutation carriers undergoing routine mammographic screening have demonstrated that approximately 50% of the breast tumors are detected at screening and 50% present as interval cancers between screening mammograms.^{5,6}

Contrast-enhanced magnetic resonance imaging (MRI) of the breast has been shown to have high sensitivity for detecting early breast cancer, albeit with lower specificity than mammography, and is not affected by breast density.⁷ A number of studies have suggested that MRI surveillance may benefit women at high risk⁸⁻¹⁵ but the sensitivity and specificity of MRI for *BRCA* mutation carriers have not been fully evaluated in the screening setting. Ultrasound of the breast is less practical than mammography for screening the general population because of its lower specificity and its dependency on operator experience.¹⁶ However, it has been found in several studies¹⁷ that ultrasound is more sensitive than mammography for screening women with dense breasts, and ultrasound may be particularly useful for the surveillance of young women at high risk.

To determine the extent to which MRI and ultrasound increase the ability to detect small breast cancers in *BRCA1* and *BRCA2* mutation carriers beyond that of mammography and CBE, and to estimate the sensitivity of this combined screening regimen, we screened 236 mutation carriers with all 4 modalities on an annual basis for up to 3 years.

METHODS

Study Population

Between November 3, 1997, and March 31, 2003, 236 female *BRCA1* and *BRCA2* mutation carriers between 25 and 65 years were recruited from familial cancer clinics in southern Ontario and Montreal, Canada. Women with a past history of unilateral breast cancer were eligible if the contralateral breast was intact. Pregnant or lactating women were asked to defer their

participation. Women with a history of bilateral breast cancer, who were currently undergoing chemotherapy, or who were known to have metastatic disease were excluded. Women who weighed more than 91 kg were excluded for technical reasons. Participation in the study was offered to all eligible women in the context of genetic counseling. Women were invited to contact the study coordinator (K.A.H.) directly if they wished to participate. Informed consent was obtained from all participants. Preliminary results for the first round of screening of the first 96 patients were reported in a previous publication.¹⁸

Study Protocol

The study was approved by the institutional review boards of the participating institutions. Eligible women were invited to begin the screening protocol after at least 1 year had passed since their last mammogram. The protocol consisted of an intake questionnaire that included, among other demographic factors, an open-ended question on maternal and paternal ethnicity (included because we thought the information might be meaningful), and evaluation by 4 screening modalities: CBE, mammography, screening ultrasound, and MRI. All 4 were performed on the same day at the Sunnybrook campus of the Sunnybrook and Women's College Health Sciences Centre, Toronto, Ontario. For premenopausal women, screening was performed during the second week of the menstrual cycle to minimize the occurrence of breast densities or of enhancing masses related to cyclical hormonal variation. For women with a past history of breast cancer who had undergone breast-conserving surgery, bilateral breast screening was performed. For those women who had undergone unilateral mastectomy, screening of the contralateral breast was performed. Each imaging study was read and scored independently by a different radiologist (P.A.C. and R.A.J.) who specialized in breast imaging. Radiologists were blinded to the results of the CBE. Imag-

ing was repeated annually and CBE was performed every 6 months.

Clinical Breast Examination

Physical examination of the breasts and regional lymphatic areas was performed at 6-month intervals by either a physician or a registered nurse (E.W., M.R.C., and S.J.M.) experienced in breast examination. Each examination was coded as normal, suggestive of benign disease, indeterminate, or suspicious for malignancy. Indeterminate examinations were repeated 3 months later.

Mammography

Conventional 4-view film/screen mammograms were reviewed by a single radiologist (P.A.C. or R.A.J.). Further views were performed when judged to be necessary. Mammograms were scored on a 5-point scale, using the American College of Radiology Breast Imaging Reporting and Data System (BI-RADS) categories (0=needs further work-up; 1=negative; 2=benign finding; 3=probably benign finding, short follow-up interval suggested; 4=suspicious abnormality, biopsy should be considered; 5=highly suggestive of malignancy).¹⁹

Magnetic Resonance Imaging

Simultaneous bilateral MRI was performed by using a 1.5-T magnet (Signa, General Electric Medical Systems, Milwaukee, Wis). The first 38 patients were imaged in the first year of the study with a single turn elliptical coil after a bolus injection of 0.1 mmol/kg of gadolinium-diethylenetriamine penta-acetic acid (Omniscan, GE Healthcare, Oakville, Ontario). After appropriate imaging to localize the breast, bilateral 3-dimensional spoiled gradient recalled images (SPGR) were collected in the coronal plane (repetition time [TR]/echo time [TE]/flip angle, 12.9 ms/43 ms/20° with 28 slices of 4-6 mm thickness), preinjection, and for a period of 10 minutes postinjection. The scan time for each 3-dimensional data set was 90 seconds. For all subsequent scans, a phased-array coil arrangement was used,²⁰ which

provided sagittal images with a 2.5-fold greater signal-to-noise ratio. The protocol includes a localizing sequence, sagittal, fat-suppressed T2-weighted Fast Spin Echo (TR/TE, 4000 ms/102 ms), followed by simultaneous sagittal imaging of both breasts using dual 3-dimensional sagittal TR-interleaved SPGR sequences (TR/TE/flip angle, 18.4 ms/4.3 ms/40° from 28 partitions per breast) as proposed by Greenman et al.²¹ Imaging was performed both before and after a rapid intravenous injection of 0.1 mmol/kg of gadolinium-diethylenetriamine pentaacetic acid. Each volumetric bilateral acquisition was obtained in 2 minutes 49 seconds. Slice thickness was 2 to 3 mm, without a gap, using a matrix of 256 × 256 and a field of view of 18 to 20 cm. Frequency was in the anteroposterior direction. Precontrast images were subtracted from postcontrast images to suppress the fat signal.

In cases in which a potentially suspicious area of enhancement was detected, a diagnostic MRI scan was performed, which comprised a set of high temporal and spatial resolution unilateral MRI scans of the suspicious breast. During the first 2 minutes postinjection, dynamic images were acquired in the form of 9 adjacent, 2-dimensional SPGR with fat saturation (TR/TE/flip angle, 150 ms/4.2 ms/50°) that allowed dynamic monitoring of tissue enhancement with a temporal resolution of 20 seconds. This was followed by a single high spatial resolution 3-dimensional SPGR scan with fat saturation (TR/TE/flip angle/matrix/slice thickness, 50 ms/4.2 ms/50°/256 × 512/1 mm) that took 7 minutes. This was then followed up by an additional series of dynamic images to monitor contrast media washout. The scanning time for the entire set of images was 10 minutes. These images were used to help further characterize the lesion morphology and to provide kinetic enhancement characteristics for clinical management.

The MRI results were initially scored according to the preliminary BI-RADS classification.²² Assessment was based primarily on morphology, using en-

hancement kinetics for indeterminate and presumed benign lesions.²³ The criteria included mass vs nonmass enhancement and symmetry of enhancement. Enhancement patterns were assessed both qualitatively and quantitatively, using time-signal intensity curves (including the degree of enhancement and the delayed enhancement pattern). Cases with a detected abnormality were classified as follows. Cases for which the diagnosis of a specific benign condition was presumed (the presence of nonenhancing internal septations in a circumscribed or lobulated mass with no washout on delayed imaging for fibroadenoma, rim enhancement associated with an inflamed cyst, or a reniform shaped intramammary lymph node with a feeding vessel to the hilum) were classified as BI-RADS 2.^{22,24} Cases with a focus or a symmetric diffuse enhancement pattern were also classified as BI-RADS 2.²² Nonmass lesions with features that were predictive of malignancy (asymmetric clumped enhancement in a ductal, linear, or segmental distribution) were classified as BI-RADS 4.^{22,24-27} Masses that possessed features that were predictive of malignancy (spiculated or irregular margins, rim enhancement, irregular shape associated with early enhancement with washout during delayed phase) were classified as BI-RADS 5. If a mass did not possess features whereby a specific benign condition could be diagnosed, it was considered to be BI-RADS 4 or 5. Masses that were believed to be due to fibroadenomas or to intramammary lymph nodes but could not be confidently classified as such, or asymmetric nonmass enhancements that did not fall into the previously mentioned categories, were classified as BI-RADS 3. Women with BI-RADS 3 lesions did not routinely undergo biopsy but were followed up at 6 months, 1 year, and 2 years after the initial imaging study. If a lesion resolved, decreased, or remained stable during 2 years, it was reclassified as BI-RADS 2.

Ultrasound

High-resolution ultrasound was performed using a 7.5-MHz transducer by

a technologist supervised by an experienced physician (P.A.C. or R.A.J.) and blinded to the other imaging studies. The reports were coded using a preliminary BI-RADS ultrasound lexicon.²⁸ Any solid lesion, unless benign by criteria established by Stavros et al,²⁹ was considered to be suspicious enough for cancer to warrant a biopsy. The first 7 patients did not receive ultrasound.

Biopsies

A biopsy was recommended if 1 of CBE, mammogram, MRI examination, or ultrasound was judged to be suspicious for cancer (BI-RADS categories: 4 or 5 or equivalent). If the MRI screening test was abnormal (BI-RADS: 3, 4, or 5) but no other modality was abnormal, a diagnostic MRI procedure was performed approximately 4 weeks later. Cases that were suspicious for malignancy on diagnostic MRI examination (BI-RADS: 4 or 5) proceeded to biopsy. If a lesion was detected only by MRI, the mammograms were reviewed and a targeted second-look ultrasound was performed to help guide the biopsy. Any lesion detected by the targeted ultrasound was correlated with the MRI by lesion morphology, size, and location to ensure that the ultrasound visible lesion corresponded with the MRI lesion prior to biopsy.

Core and excisional biopsies were performed under ultrasound or stereotactic guidance, with the exception of 10 women for whom the abnormality was visualized by MRI but was not observed with directed ultrasound or mammography. In these cases an excisional biopsy was performed using an MRI-guided wire localization technique^{30,31} similar to that proposed by Orel et al.³² This device consisted of 2 fenestrated plates that provide medial-lateral compression of the breast. Fine needle positioning within these fenestrations (a set of 6 × 8 square, 5/8" apertures) was performed using guide plugs accommodating needles of various gauge sizes (20, 14, and 9 gauges). These drilled guide holes provided a means of delivering the needle into the breast through a finite number of positions. Attached to these

Table 1. Characteristics of Study Participants (N = 236)

Characteristics	No. of Participants (%)
Age at first screening, mean (range), y	46.6 (26.4-64.8)
Mutation status	
BRCA1	137 (58)
BRCA2	99 (42)
Ethnicity*	
Ashkenazi Jewish	73 (31)
Other	163 (69)
Cancer history	
Breast	70 (30)
Ovary	22 (9)
None or other	144 (60)
Menopausal status	
Premenopausal	106 (45)
Postmenopausal	130 (55)
Rounds of screening completed	
1	236 (100)
2	136 (58)
3	85 (36)

*Ethnicity was indicated by study participant via a questionnaire.

compression plates was a pair of fiducial markers positioned at known locations relative to the fenestrations. This configuration enabled stereotactic needle delivery with the option of medial or lateral approach, using computer program assistance to calculate the appropriate fenestration, guide hole, and needle insertion depth into the tumor for biopsy of wire localization. Using this apparatus, we have subsequently performed percutaneous MRI-guided biopsies using 14-gauge and 9-gauge vacuum assisted devices for MRI-only visualized BI-RADS 4 and 5 lesions as described previously.³³⁻³⁵ These cases are not included in this patient cohort.

Prior to biopsy for suspected interval cancers (presenting between scheduled rounds of imaging and CBE), repeat imaging with mammography, ultrasound, and MRI was performed.

Follow-up

Patients were followed up annually by questionnaire to determine whether any cancers had been diagnosed since the last screening interval. All study participants were followed up for 1 year from the date of the last screening examination and all new cancers and prophylactic mastectomies were recorded. Study participants who completed at least 1 screening examina-

tion but who left the study for any reason before completing 3 screening rounds were also followed up.

Statistical Analysis

Sensitivity was defined as the number of cancers detected by a given modality (or combination of modalities) divided by the total number of cancers detected by all 4 modalities plus interval cancers during the entire 3-year study period (from the date of first screen to 1 year following the last screen). Differences in the relative sensitivity of each modality were compared with Fisher exact test. As sensitivities of overlapping combinations of screening modalities are not independent when applied to the same patients without blinded repetition, statistical testing of comparisons between them was not performed. The positive predictive value (PPV) for each modality was defined as the number of biopsy-proven cancers as a proportion of the number of suspicious studies (BI-RADS: 4 or 5 or equivalent) that resulted in a biopsy. Specificity was defined as the number of true-negative results divided by the sum of true-negative results and false-positive results (ie, examinations leading to a negative biopsy). These definitions of PPV and specificity did not include in the denominators women who had additional diagnostic studies that did not result in a biopsy. The negative predictive value was defined as the number of true-negative results as a fraction of the total number of true-negative and false-negative studies. The change in the benign biopsy rate with successive rounds of screening was tested for statistical significance using a χ^2 test for trend. Because sensitivity and specificity vary with the chosen operating point (ie, the minimum BI-RADS score at which a report is considered to be positive), receiver operating characteristic (ROC) curves were plotted by using Microsoft Excel (Microsoft Corp, Redmond, Wash) and the corresponding areas under the ROC curve determined. The CBEs coded as suspicious for malignancy were recorded as BI-RADS 4 for the purpose of ROC curve construction.

RESULTS

The characteristics of the 236 study participants are listed in TABLE 1. The mean (range) age of participants at first screening was 46.6 years (26.4-64.8 years). A total of 205 women (87%) had a mammogram in the 15 months before starting the study. All women (100%) completed at least 1 round of screening, 136 (58%) completed at least 2 rounds, and 85 (36%) completed all 3 rounds. A total of 120 women are still undergoing annual screening. Thirty-one women left the study before completing all 3 rounds; 16 underwent bilateral mastectomy, 3 were too large to fit into the MRI machine, 3 stopped their participation due to pregnancy, 4 developed metastatic cancer, 4 were lost to follow-up, and 1 no longer wished to participate.

Breast Cancers

A total of 22 cancers (16 invasive and 6 ductal carcinoma in situ [DCIS]) were found in 21 women (1 woman had bilateral cancer). Multicentric cancer in 1 breast was defined as a single cancer. The characteristics of the patients with cancer, screening results, and tumor stage are listed in TABLE 2. The mean (range) age of the 21 women with cancer was 47.4 years (33.4-63.0 years). Seven women (33%) had previous breast cancer. Of the 22 cancers, 2 (9.1%) were detected by CBE, 8 (36%) by mammography, 7 (33%) of 21 by ultrasound, and 17 (77%) by MRI. Magnetic resonance imaging was significantly more sensitive than either mammography ($P = .02$) or ultrasound ($P = .006$).

All patients were followed up for a minimum of 1 year from the date of the last imaging examination. There was only 1 interval cancer, detected in a 40-year-old BRCA1 mutation carrier 7 months after her third screen (patient 59). At the time of her diagnosis, the tumor was visible with all 3 imaging modalities. In retrospect, it could be observed on previous screening MRI and mammogram. It is not possible to determine retrospectively if it was evident on ultrasound. Another woman (patient 323), who elected to have bi-

lateral mastectomy after her breast cancer was found, had a 2-mm focus of DCIS in the contralateral breast, which had not been detected 2 months earlier by any screening modality.

In combination, all 4 screening modalities had a sensitivity of 95% compared with 45% for mammography and CBE combined. By omitting ultrasound from the screening regimen, the overall sensitivity decreased from 95% to 86%. The sensitivity of all modalities other than MRI was 64%. The ROC curves for the entire BI-RADS range are shown in FIGURE 1. Seven cancers (32%) were detected by MRI but missed by all other modalities. Two cancers were detected by mammography alone (9.1%) and 2 detected by ultrasound alone (9.5%). Magnetic resonance imaging detected 9 (75%) of 12 cancers missed by conventional surveillance (mammography and CBE). Several of

these cancers were in patients with relatively fatty breasts (FIGURE 2). Ductal carcinoma in situ accounted for 6 (55%) of 11 cancers in *BRCA2* mutation carriers but there were no cases of DCIS alone (without associated invasion) among the *BRCA1* mutation carriers.

The mean sizes of the invasive cancers on the first and second rounds of screening were 1.1 cm and 1.3 cm, respectively. For the 3 patients who had tumor sizes of more than 1 cm during the second round of screening, the mammogram and MRI study from the previous year were reviewed to determine whether the tumors could be observed in retrospect. The tumor of patient 87 could not be observed on the mammogram or MRI of the previous year. The tumor of patient 210 could not be observed on the MRI of the previous year but a few calcifications were present on the previous mammogram.

The invasive tumor of patient 225 could be observed in retrospect on the MRI of the previous year, at which time it measured 8 mm.

Seventy of 236 study participants had previous breast cancer. Of the 70 women with previous breast cancer, there were 131 examinations performed and 6 cancers (4.6%) were detected (3 invasive and 3 DCIS). Of the 166 women with no previous breast cancer, there were 326 examinations performed and 16 cancers (4.9%) detected (12 invasive and 4 DCIS). Only 2 women had node-positive breast cancer (9% of all cancers). Both were found on the first round of screening. All 22 patients who had cancer detected are currently alive and disease-free.

False-Positive Screens

After the first round of screening, 16.5% of participants underwent a diagnos-

Table 2. Characteristics of Patients With Cancer, Screening Results, and Tumor Stage

Patient	Screen	Age, y	Mutation	Previous Breast Cancer	CBE	Mammography	Ultrasound	MRI	Histology	Size, cm	Nodal Status
5*	1	51	<i>BRCA1</i>	None	–	–	–	+	ID	0.5	–
15*	1	51	<i>BRCA2</i>	Contralateral	–	+	–	–	DCIS	†	NP
19*	1	46	<i>BRCA1</i>	None	–	–	–	+	ID	0.5	–
23*	1	49	<i>BRCA2</i>	None	+	–	NP	+	ID	1.0	–
45	2	47	<i>BRCA2</i>	None	–	–	+	+	ID	0.7	–
59	3‡	40	<i>BRCA1</i>	None	NP§	–	–	–	ID	1.7	–
63*	1	52	<i>BRCA1</i>	Contralateral	–	+	+	+	ID	0.7	–
87	2	44	<i>BRCA1</i>	None	–	+	+	+	ID	1.5	–
122*	1	33	<i>BRCA1</i>	Contralateral	–	+	+	+	ID	1.0	–
141	2	38	<i>BRCA2</i>	None	–	+	–	–	DCIS	†	NP
210	2	54	<i>BRCA1</i>	None	–	+	–	+	ID	2.0	–
215	2	50	<i>BRCA1</i>	None	–	–	–	+	ID	0.6	–
225	2	39	<i>BRCA2</i>	None	–	–	+	–	ID	1.5	–
225	3	40	<i>BRCA2</i>	Contralateral	–	–	–	+	DCIS	6.0	NP
283	2	53	<i>BRCA1</i>	None	–	–	+	+	ID	1.0	–
323	1	48	<i>BRCA1</i>	Ipsilateral (different quadrant)	–	+	–	+	ID	1.0	NP
346	1	46	<i>BRCA2</i>	None	–	+	–	+	DCIS	1.5	NP
347	1	54	<i>BRCA2</i>	Ipsilateral (different quadrant)	+	–	–	+	DCIS	3.0	NP
358	1	63	<i>BRCA2</i>	Contralateral	–	–	–	+	DCIS	4.0	NP
384	1	35	<i>BRCA2</i>	None	–	–	–	+	ID	2.0	–
396	1	50	<i>BRCA1</i>	None	–	–	–	+	ID	1.5	5/11
412	1	60	<i>BRCA2</i>	None	–	–	+	–	IL	1.9	1/17

Abbreviations: CBE, clinical breast examination; DCIS, ductal carcinoma in situ; ID, infiltrating ductal; IL, invasive lobular; MRI, magnetic resonance imaging; NP, not performed.

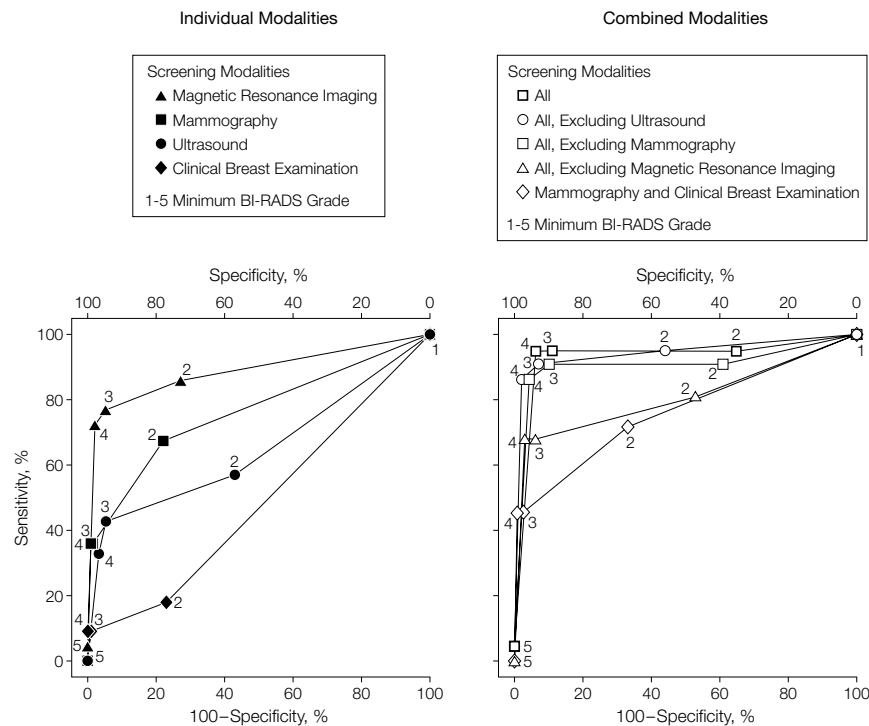
*Indicates the 6 patients whose tumors have been previously reported.¹⁸

†For patient 15, no size measurement was given because specimen consisted of few very small scattered foci; for patient 141, no remaining cancer was observed at time of the excisional biopsy.

‡Interval cancer detected 7 months after third screening (year 3).

§Third annual CBE was performed at time of imaging but subsequent 6-month CBE was missed.

Figure 1. Receiver Operating Characteristic Curves for Magnetic Resonance Imaging, Mammography, Ultrasound, and Clinical Breast Examination

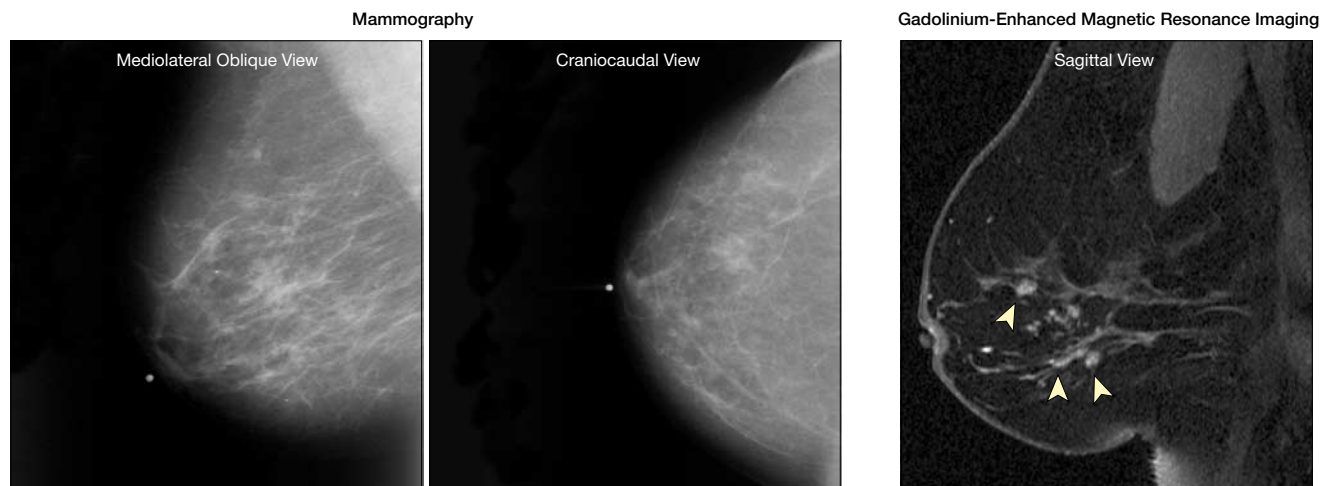


Numbered data points indicate the sensitivity and specificity obtained if the minimum Breast Imaging Reporting and Data System (BI-RADS) grade for a positive point is varied from 1 to 5. For individual modalities, the areas under the receiver operating characteristic (ROC) curves are 0.89 for magnetic resonance imaging (MRI), 0.77 for mammography, 0.65 for ultrasound, and 0.48 for clinical breast examination (CBE). For combinations of modalities, the areas under the ROC curves are 0.93 for all 4 modalities, 0.94 for all excluding ultrasound, 0.91 for all excluding mammography, 0.81 for all excluding MRI, and 0.77 for mammography and CBE.

tic MRI scan to clarify the status of an indeterminate or possibly suspicious lesion. This rate decreased at the second and third rounds of screening to 9.6% and 7.1%, respectively. For an additional 7.6% of the patients, a 6-month follow-up MRI was recommended for lesions that remained indeterminate. This rate decreased at the second and third screens to 2.9% and 2.4%, respectively. In the first round of screening, 5.1% of ultrasound examinations and 0.4% of mammograms resulted in the recommendation of a 6-month follow-up examination. A total of 2.1% of CBEs were also thought to be suspicious at the first round and CBE was repeated 3 months later. The corresponding rates for the second and third years combined were 3.2% for ultrasound, 0% for mammograms, and 0.4% for CBE.

A total of 34 (14%) of 236 women in the study have had a biopsy for what proved to be benign disease. Five women (2.1%) have had more than 1 biopsy. The benign biopsy rate was significantly higher at the first round of screening (26 [11%] of 236) than at the second (9 [6.6%] of 136) or third round (4 [4.7%] of 85; $P = .05$). Only 5.1% of all benign biopsies were generated by a CBE

Figure 2. Mammography and Magnetic Resonance Imaging in BRCA2 Mutation Carrier With Less Than 25% Fibroglandular Density



False-negative mammograms in a 63-year-old BRCA2 mutation carrier demonstrating normal-appearing breasts that are composed of mostly fat (<25% fibroglandular density), classified as Breast Imaging Reporting and Data System (BI-RADS) 1. Sagittal, gadolinium-enhanced, fat-suppressed 3-dimensional spoiled gradient recalled magnetic resonance image of the right breast reveals clumped enhancement of more than 3.4 cm in a ductal distribution (arrowheads), classified as BI-RADS 4. Magnetic resonance imaging-guided wire localization and excisional biopsy revealed ductal carcinoma in situ.

or a mammography finding; the rest were due to MRI or ultrasound. The PPV and specificity of MRI and ultrasound by year are given in TABLE 3. The PPV of MRI is consistently higher than that of ultrasound. The specificity of MRI is relatively low in the first year of screening compared with subsequent years. Of the 32 biopsies necessitated by findings with MRI alone, 22 (69%) could be performed under directed ultrasound guidance. The most common benign pathological findings were fibroadenoma (38%), fibrocystic changes (31%), and dense fibrosis (7.7%).

COMMENT

This study of 236 *BRCA1* and *BRCA2* mutation carriers demonstrates that the addition of annual MRI and ultrasound to mammography and CBE significantly improves the sensitivity of surveillance for detecting early breast cancers. The combination of MRI, ultrasound, and mammography had a sensitivity of 95% compared with 45% for mammography and CBE. Magnetic resonance imaging alone had a sensitivity of 77%. This study extends our study sample from our previous 96 to 236 *BRCA* carriers.¹⁸ Previously, we reported the results of the first screening examination only; however, now we report an average of 1.9 screening examinations per patient.

Only 36% of the breast cancers were detected by mammography. The sensitivity of mammography is inversely related to breast density and breast density is much higher, on average, in younger women than in older women.³⁶ Furthermore, *BRCA1*-related cancers tend to be cellular with round pushing margins rather than scirrhous with irregular infiltrating margins, resulting in a more benign mammographic appearance.³⁷ *BRCA1*-associated tumors are also less likely to be associated with DCIS, which often develops microcalcifications that lead to detection by mammography, than are nonhereditary cancers or breast cancers in *BRCA2* carriers.^{38,39}

The sensitivity of mammography in mutation carriers has been measured in

Table 3. Comparative Sensitivity, Specificity, Positive and Negative Predictive Values of Mammography, Ultrasound, and MRI by Year

	Mammography			Ultrasound			MRI		
	Year 1	Year 2	Year 3	Year 1	Year 2	Year 3	Year 1	Year 2	Year 3
Total screens, No.	236	136	85	229	136	85	236	136	85
Positive screen, No.									
True-positive	5	3	0	3	4	0	11	5	1
False-positive	1	0	0	10	5	2	15	4	1
Negative screen, No.									
True-negative	222	129	83	207	124	81	208	125	82
False-negative	8	4	2	9	3	2	2	2	1
Sensitivity, %	38	43	0	25	57	0	85	71	50
Specificity, %*	99.6	100	100	95	96	98	93	97	99
Predictive value, %									
Positive	83	100	NA	23	44	0	42	56	50
Negative	97	97	98	96	98	98	99	98	99

Abbreviations: MRI, magnetic resonance imaging; NA, not applicable.

*Definition of specificity is based on biopsy rates.

several retrospective studies. In a small study⁴⁰ of Asian patients with palpable breast cancers, only 4 (44%) of 9 tumors detected in *BRCA1* mutation carriers could be observed on the preoperative mammogram (mean size, 4.1 cm) compared with 18 (95%) of 19 tumors in age-matched noncarriers ($P=.03$). Similarly, in a study of Ashkenazi Jewish women diagnosed with breast cancer younger than 50 years in Montreal,⁴¹ with breast cancers less than or equal to 2 cm in size, only 2 (25%) of 8 breast cancers could be observed on the preoperative mammogram of the mutation carriers compared with 27 (77%) of 35 in noncarriers ($P=.009$).

Prospective studies of cohorts undergoing mammographic surveillance have also been discouraging. In a series of 128 *BRCA1* and *BRCA2* mutation carriers reported by Brekkelmans et al,⁵ 9 invasive breast cancers were detected after a median follow-up of 3 years. Five (56%) of the cancers were node-positive, 7 (78%) were more than 1 cm in size, and 4 (44%) appeared between rounds of screening mammography. Scheuer et al⁶ followed 164 mutation carriers for a mean of 2 years. Of the 10 cancers detected in women undergoing conventional surveillance only (mammography and breast self-examination), 2 (20%) were node-positive, 4 (40%) were more than 1 cm in size, and 5 (50%) were detected be-

tween screening mammograms. In contrast with these 2 studies, the proportion of interval cancers in our study was only 5%.

Although from a single center, our study is the largest study published to date of women with *BRCA1* and *BRCA2* mutations and the only one to include 4 screening modalities performed on the same day. Other preliminary reports of surveillance studies for high-risk women have also demonstrated better sensitivity of MRI compared with mammography.⁸⁻¹⁵ However, most previous studies included a relatively small number of patients with documented *BRCA* mutations and follow-up periods were short. In a large screening study of 196 high-risk women, Kuhl et al¹³ found 36 cancers. The sensitivity of MRI was 95% vs 34% for mammography and 42% for ultrasound. Morris et al¹⁰ screened 367 women at high risk for breast cancer using MRI. Biopsies were recommended for 64 women and 14 cancers were detected (8 DCIS and 6 invasive). These 2 single center studies were not restricted to *BRCA* mutations carriers. A total of 210 *BRCA1* and *BRCA2* mutations carriers have been included in a multicenter study from the Netherlands but only preliminary results have been published.¹¹

It is expected that cancers detected at the first round of screening (prevalent cancers) should be larger and more

likely to be lymph-node positive than cancers detected at subsequent screens (incident cancers). Three (23%) of 13 cancers detected at the first screen were more than 1 cm in size and 2 had axillary node involvement. Three (43%) of 7 cancers detected at the second screen were more than 1 cm in size but none were node-positive. The prevalence of cancer on the second screen (5.1%) was not appreciably lower than the proportion found to have cancer on the first screen (5.5%). There are 2 possible explanations for these unexpected findings. Subtle MRI changes on the first screen could have been missed, either because of relative lack of experience performing or reading MRI at the beginning of the study or because no previous MRI scan was available for comparison. Alternatively, the cancers could have grown so rapidly that, although undetectable at the first screen, within 1 year had grown beyond 1 cm. If rapid tumor growth is typical of BRCA-associated cancers, screening at 6-month intervals should be considered. Although the numbers are small, this is not supported by our year 3 results.

Ductal carcinoma in situ without invasion was only found in the BRCA2 mutation carriers. Other investigators have commented on the relative lack of DCIS in BRCA1 mutation carriers^{38,39} and suggest that among BRCA1 mutation carriers invasion occurs at an early stage of tumor development. Mammography appears to be a valuable adjunct to MRI for BRCA2 carriers because of the high incidence of DCIS in this subgroup. However, because of concerns about the potential carcinogenicity of ionizing radiation in younger women in general⁴² and BRCA1 mutation carriers in particular,⁴³ some authors⁴⁴ have suggested omitting mammography from the surveillance regimen for BRCA1 mutation carriers younger than 35 years.

To date, the reluctance to use breast MRI for surveillance of high-risk women outside the context of a clinical trial relates, to a large extent, to its high cost and relatively low specificity

compared with mammography.⁴⁵ It is encouraging that the MRI recall rates in our study decreased substantially from 26% on the first round of screening to 13% on the second round and 10% on the third round. Our overall specificity of 95% and PPV of 46% for MRI is comparable with the results of other investigators who have reported specificity rates ranging from 88% to 98% and PPVs ranging from 24% to 71%.^{8,10,13} Moreover, our results improved with successive rounds of screening. In all these studies, the definitions of specificity and PPV are based on biopsy rates rather than the number of screens requiring further work-up. Two of the cancers in our study were detected by ultrasound alone. However, including ultrasound in the protocol resulted in more additional biopsies than MRI after the first year of screening. Whether the benefit of ultrasound is justified in light of the high false-positive rate remains to be observed. We did not observe any benefit from CBE over and above the combination of the 3 imaging modalities.

In conclusion, our results support the position that MRI-based screening is likely to become the cornerstone of breast cancer surveillance for BRCA1 and BRCA2 mutation carriers, but it is necessary to demonstrate that this surveillance tool lowers breast cancer mortality before it can be recommended for general use.

Author Contributions: Dr Warner had full access to all of the data in the study and takes responsibility for the integrity of the data and the accuracy of the data analysis.

Study concept and design: Warner, Plewes, DeBoer, Yaffe, Narod.

Acquisition of data: Warner, Plewes, Hill, Causser, Zubovits, Jong, Cutrara, Messner, Meschino, Piron, Narod.

Analysis and interpretation of data: Warner, Hill, Causser, Jong, DeBoer, Yaffe, Narod.

Drafting of the manuscript: Warner, Plewes, Narod. **Critical revision of the manuscript for important intellectual content:** Hill, Causser, Zubovits, Jong, Cutrara, DeBoer, Yaffe, Messner, Meschino, Piron.

Statistical analysis: DeBoer, Narod.

Obtained funding: Warner, Plewes.

Administrative, technical, or material support: Plewes, Hill, Causser, Jong, Cutrara, Yaffe, Piron, Narod.

Study supervision: Warner, Plewes.

Funding/Support: This work was supported by grants from the Canadian Breast Cancer Research Alliance, The Terry Fox Foundation, and funding from the International Breast MRI Consortium, the (Canadian)

National Breast Cancer Fund, and the Papoff Family. The MRI contrast agent was kindly supplied by GE Healthcare.

Role of the Sponsors: The Canadian Breast Cancer Research Alliance, the Terry Fox Foundation, the International Breast MRI Consortium, the National Breast Cancer Fund, and the Papoff Family did not participate in the design and conduct of the study, in the collection, analysis, and interpretation of the data, or in the preparation, review, or approval of the manuscript.

Acknowledgment: We thank Glen Taylor, MD, Alice Chung, BSc (MTS), Joan Glazier, MRT (RCBI), Elizabeth Ramsay, PhD, Rhonda Walcarius, MRT(R), and Gina Markin, BSc, for their technical assistance; Belinda Curpen, MD, Taube Samuels, MD, Rene Shumak, MD, and Anne Marie Shorter, MD, for their interpretation of ultrasound results and mammograms; Michelle Kuzmich for helping prepare the manuscript; and the referring physicians. We are particularly grateful to the study participants.

REFERENCES

1. Ford D, Easton DF, Stratton M, et al. Genetic heterogeneity and penetrance analysis of the BRCA1 and BRCA2 genes in breast cancer families. *Am J Hum Genet.* 1998;62:676-689.
2. Daly MB, et al. The NCCN 2003 Genetic/Familial High-Risk Assessment Clinical Practice Guidelines in Oncology, version 1, 2003. Available at: <http://www.nccn.org>. Accessed August 2, 2004.
3. Burke W, Daly M, Garber J, et al. Recommendations for follow-up care of individuals with an inherited predisposition to cancer II BRCA1 and BRCA2: Cancer Genetics Studies Consortium. *JAMA.* 1997;277:997-1003.
4. Breast Cancer Screening Monograph Working Group. *IARC Handbooks of Cancer Prevention.* Vol 7. Lyon, France: International Agency for Research on Cancers Press; 2002.
5. Brekelmans CTM, Seynaeve C, Bartels CC, et al. Effectiveness of breast cancer surveillance in BRCA1/2 gene mutation carriers and women with high familial risk. *J Clin Oncol.* 2001;19:924-930.
6. Scheuer L, Kauff N, Robson M, et al. Outcome of preventive surgery and screening for breast and ovarian cancer in BRCA mutation carriers. *J Clin Oncol.* 2002;20:1260-1268.
7. Weinreb JC, Newstead G. MR imaging of the breast. *Radiology.* 1995;196:593-610.
8. Stoutjeskijk MJ, Boetes C, Jager GJ, et al. Magnetic resonance imaging and mammography in women with a hereditary risk of breast cancer. *J Natl Cancer Inst.* 2001;93:1095-1102.
9. Kuhl CK, Schmutzler RK, Leutner CC, et al. Breast MR imaging screening in 192 women proved or suspected to be carriers of a breast cancer susceptibility gene: preliminary results. *Radiology.* 2000;215:267-279.
10. Morris EA, Liberman L, Ballon DJ, et al. MRI of occult breast carcinoma in a high-risk population. *AJR Am J Roentgenol.* 2003;181:619-626.
11. Kriege M, Brekelmans CTM, Boetes C, et al. MRI screening for breast cancer in women with familial or genetic predisposition. *Fam Cancer.* 2001;1:163-168.
12. Podo F, Sardanelli F, Canese R, et al. The Italian multicentre project on evaluation of MRI and other imaging modalities in early detection of mammary tumours in subjects at high genetic risk. *J Exp Clin Cancer Res.* 2002;21(suppl 3):115-124.
13. Kuhl CK, Schradang S, Leutner CC, et al. Surveillance of "high risk" women with proven or suspected familial (hereditary) breast cancer [abstract]. *Proc Am Soc Clin Oncol.* 2003;22:2.
14. Leach MO, Eeles RA, Turnbull LW, et al. The UK national study of magnetic resonance imaging for

- screening for breast cancer (MARIBS). *J Exp Clin Cancer Res*. 2002;21:107-114.
15. Tilanus-Linthorst MM, Obdeijn IM, Bartels KC, et al. First experience in screening women at high risk for breast cancer with MR imaging. *Breast Cancer Res Treat*. 2000;63:53-60.
 16. Gordon PB. Ultrasound for breast screening and staging. *Radiol Clin North Am*. 2002;40:431-441.
 17. Kolb TM, Lichy J, Newhouse JH. Comparison of the performance of screening mammography, physical examination, and breast ultrasound and evaluation of factors that influence them. *Radiology*. 2002;225:165-175.
 18. Warner E, Plewes DB, Shumak RS, et al. Comparison of breast magnetic resonance imaging, mammography, and ultrasound for surveillance of women at high risk for hereditary breast cancer. *J Clin Oncol*. 2001;19:3524-3531.
 19. American College of Radiology (ACR) reporting system. In: *Breast Imaging Reporting and Data System (BI-RADS)*. 2nd ed. Reston, Va: American College of Radiology; 1993:15-18.
 20. Konyer NB, Ramsay EA, Bronskill MJ, Plewes DB. Comparison of MR imaging breast coils. *Radiology*. 2002;222:830-834.
 21. Greenman RL, Lenkinski RE, Schnall MD. Bilateral imaging using separate interleaved 3D volumes and dynamically switched multiple receive coil arrays. *Magn Reson Med*. 1998;39:108-115.
 22. Morris EA. Illustrated breast MR lexicon. *Semin Roentgenol*. 2001;36:238-249.
 23. Kuhl CK, Mielcarek P, Klaschik S, et al. Dynamic breast MR imaging: are signal intensity time course data useful for differential diagnosis of enhancing lesions? *Radiology*. 1999;211:101-110.
 24. Nunes LW, Schnall MD, Siegelman ES, et al. Diagnostic performance characteristics of architectural features revealed by high spatial-resolution MR imaging of the breast. *AJR Am J Roentgenol*. 1997;169:409-415.
 25. Nunes LW, Schnall MD, Orel SG, et al. Breast MR imaging: interpretation model. *Radiology*. 1997;202:833-841.
 26. Nunes LW, Schnall MD, Orel SG, et al. Correlation of lesion appearance and histologic findings for the nodes of a breast MR imaging interpretation model. *Radiographics*. 1999;19:79-92.
 27. Liberman L, Morris EA, Lee MJ, et al. Breast lesions detected on MR imaging: features and positive predictive value. *AJR Am J Roentgenol*. 2002;179:171-178.
 28. Mendelson EB, Berg WA, Merritt CR. Toward a standardized breast ultrasound lexicon, BI-RADS: ultrasound. *Semin Roentgenol*. 2001;36:217-225.
 29. Stavros AT, Thickman D, Rapp CL, et al. Solid breast nodules: use of sonography to distinguish between benign and malignant lesions. *Radiology*. 1995;196:123-134.
 30. Causer P, Piron C, Jong R, Curpen B, Hill K, Plewes D. *A Medial/Lateral Access MRI Guided Breast Localization System: Proceedings of the Radiological Society of North America, Chicago, Ill, December 2003*. Oak Brook, Ill: Radiological Society of North America; 2003.
 31. Piron CA, ed. *Hybrid Imaging Guidance System for Biopsy of Breast*. Toronto, Ontario: Dept of Medical Biophysics, University of Toronto; 2001:155.
 32. Orel SG, Schnall MD, Newman RW, et al. MR imaging guided localization and biopsy of breast lesions: initial experience. *Radiology*. 1994;193:97-102.
 33. Kuhl CK, Morakkabati N, Leutner CC, et al. MR imaging-guided large-core (14-gauge) needle biopsy of small lesions visible at breast MR imaging alone. *Radiology*. 2001;220:31-39.
 34. Liberman L, Morris EA, Dershaw DD, et al. Fast MRI-guided vacuum-assisted breast biopsy: initial experience. *AJR Am J Roentgenol*. 2003;181:1283-1293.
 35. Daniel BL, Birdwell RL, Butts K, et al. Freehand iMRI-guided large-gauge core needle biopsy: a new minimally invasive technique for diagnosis of enhancing breast lesions. *J Magn Reson Imaging*. 2001;13:896-902.
 36. Rosenberg RD, Hunt WC, Williamson MR, et al. Effects of age, breast density, ethnicity and estrogen replacement therapy on screening mammographic sensitivity and cancer stage at diagnosis. *Radiology*. 1998;209:511-518.
 37. Lakhani SR, Jacquemier J, Sloane JP, et al. Multifactorial analysis of differences between sporadic breast cancers and cancers involving *BRCA1* and *BRCA2* mutations. *J Natl Cancer Inst*. 1998;90:1138-1145.
 38. Armes JE, Venter DJ. The pathology of inherited breast cancer. *Pathology*. 2002;34:309-314.
 39. Sun CC, Lenoir G, Lynch H, Narod SA. In-situ breast cancer and *BRCA1*. *Lancet*. 1996;348:408.
 40. Chang J, Yang WT, Choo HF. Mammography in Asian patients with *BRCA1* mutations. *Lancet*. 1999;353:2070-2071.
 41. Goffin J, Chappuis PO, Wong N, Foulkes WD. Magnetic resonance imaging and mammography in women with a hereditary risk of breast cancer. *J Natl Cancer Inst*. 2001;93:1754-1755.
 42. Goss G, Sierra S. Current perspectives on radiation-induced breast cancer. *J Clin Oncol*. 1998;16:338-347.
 43. Chen JJ, Silver D, Cantor S, et al. *BRCA1*, *BRCA2*, and Rad 51 operate in a common DNA damage response pathway. *Cancer Res*. 1999;59:17525-17565.
 44. Narod S, Lubinski J. Roles of radiation dose, chemotherapy and hormonal factors in breast cancer following Hodgkins disease. *J Natl Cancer Inst*. 2003;95:1552.
 45. Warren R. Screening women at high risk of breast cancer on the basis of evidence. *Eur J Radiol*. 2001;39:50-59.